

Chaput Tubercle Fracture in an Adult- A Rare Case Report

PANKAJ KUMAR MISHRA¹, VIKRAM PATIDAR², SATYA PRAKASH SINGH³

ABSTRACT

Chaput tubercle fracture occurs at the antero-lateral position of the distal tibia in adult as a counterpart of adolescent Tillaux fracture. It is a case of adult male which presented to us with onset of acute pain, swelling and restricted movements of ankle after a road side accident. A clinical diagnosis of Chaput tubercle fracture was established after a CT-scan. The displaced fracture was managed by open reduction and internal fixation by screw. At the end of follow up, the foot and ankle ability score measured. Through this case report we convey that Chaput tubercle fracture in an adult is a rare entity.

CASE REPORT

A 33-year-old male presented to the casualty of the hospital after encountering a road accident about an hour ago. The patient experienced a head on collision with another bike while driving his two wheeler. The patient complained of pain, contusion and swelling over the anterior aspect of left ankle. On examination, tender swelling with pain and restricted movement of ankle was noted. No associated history of vomiting, unconsciousness or any related injuries was found except the superficial abrasion over the dorsum of ipsilateral hand.

The antero-posterior and lateral X-rays were carried out which revealed a suspicious intra-articular fracture of the antero-lateral part of the distal tibia. For the diagnostic confirmation the CT- scan of the left ankle was done, which confirmed the displaced Chaput tubercle fracture [Table/Fig-1,2].

The informed consent was taken from the patient and surgical intervention was planned. The antero-lateral approach was used for the open reduction. Intraoperatively the K-wire was used to manipulate the fracture as a "joystick" and fixed with cannulated 4 mm lag screw [Table/Fig-3]. Postoperatively the POP slab and IV antibiotics (ceftriaxone and amikacin for three days) was given. Sutures were removed and ankle movement was started on postoperative day 11. Full range of movement was achieved in the next six days. Partial weight bearing started at sixth weeks of followup and the full weight bearing allowed at 10th weeks. Patient was on regular follow up for one year and the Foot and Ankle Ability

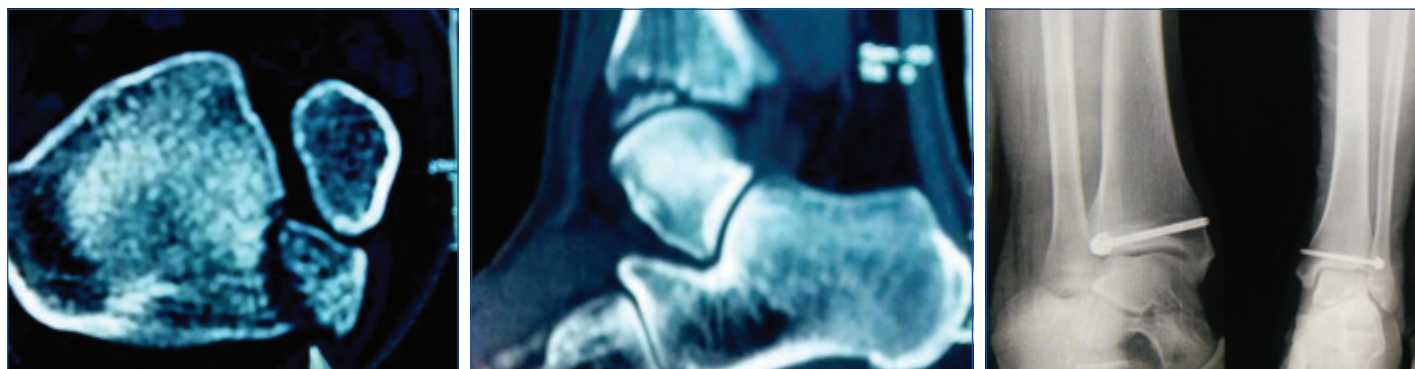
Keywords: Antero-lateral, Avulsion fracture, Distal tibial epiphysis

Measure (FAAM) score was 97% (100/116) and the patient has satisfactory clinico-radiological union [Table/Fig-4,5].

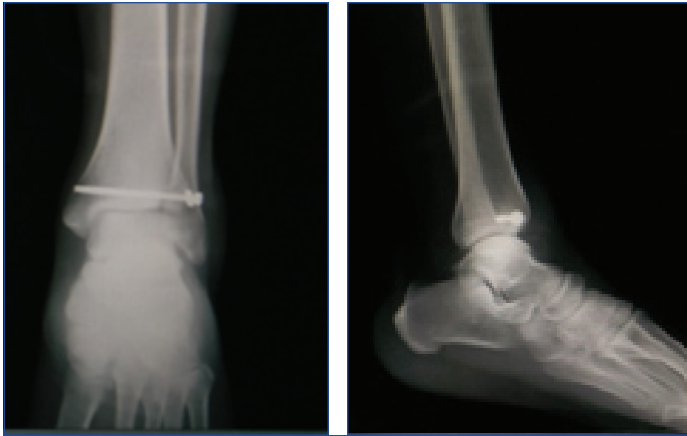DISCUSSION

Tillaux fracture occurs at the antero-lateral part of the lower end of tibial epiphysis and has a tendency to be displaced with the variable amounts. The epiphysis of distal tibia starts fusing from the middle, and first goes medially then the lateral side (12-14 years in female and 15-18 years in male). So that in the adolescent age group the Tillaux fracture is common because the lateral side of distal tibia is about to fuse which make it vulnerable for being avulsed when the anterior-inferior tibiofibular ligament (usually stronger than physis) fails to rupture during external rotation injury in the adolescents [1]. Since it is the transition period of epiphysiodesis which occurs during the adolescence to skeletal maturity so also known as transition fracture. The transition fracture of ankle is classified by Von Laer L as biplane and triplane fracture and the biplane fracture of epiphysis is analogous to Tillaux fracture [2].

The triplane fracture of the lower tibial epiphysis was first described by Marmor and has transverse component through growth plate, coronal component through posterior tibial metaphysic (Salter-harris type II or IV in lateral view) and sagittal component (Salter-harris type III in AP view) in distal tibial epiphysis [3]. On the contrary the Tillaux fracture is a biplane fracture, so the radiological diagnosis of Tillaux fracture is utterly arduous due to the lack of coronal component of the fracture as the triplane (Marmor-Lynn) fracture [4].



[Table/Fig-1]: Computed tomography showing the displaced antero-lateral part of the distal tibia. **[Table/Fig-2]:** In the sagittal section of computed tomography showing the intra-articular confinement of the avulsion. **[Table/Fig-3]:** Immediate postoperative oblique and AP view of Chaput tubercle fracture.



[Table/Fig-4]: One-year-old follow-up AP view of fixed Chaput tubercle fracture.

[Table/Fig-5]: One-year-old follow-up oblique view of the fixed Chaput tubercle fracture.

Since the traditional radiography is not always sufficient to confirm the diagnosis, so the CT scan becomes necessary to understand the fracture orientation to clinch the diagnosis.

Usually in the adult the ligament is supposed to rupture before the avulsion fracture of antero-inferior part of tibial plafond due to epiphysiodesis. So, the avulsion fracture of antero-inferior part of distal tibia (rather than ligament rupture) in adult becomes the rarebit finding (Chaput tubercle fracture) which entails it as a rare entity [5].

Non-displaced fracture ($\leq 2\text{mm}$ displacement) can be managed conservatively by long leg cast with internally rotated foot. Since the strong antero-inferior ligament is attached to the fibula, it renders it displaced and angulated [6]. So the displaced fracture is managed by close/open reduction and internal fixation [7].

In our case, the open reduction was done by antero-lateral approach and fracture segment was fixed by screw.

CONCLUSION

Chaput tubercle fracture is an unusual fracture in adult. The conventional radiology may not suffice to clinch the diagnosis sometimes. Due to the displacement and angulations, it can be better managed by surgery.

REFERENCES

- [1] Hasler C, Hardegger F. Fracture of the Tillaux-Chaput tubercle—a case from pediatric traumatology. *Z Unfallchir Versicherungsmed.* 1993;86(3):149-51.
- [2] Von Laer L. Classification, diagnosis, and treatment of transitional fractures of the distal part of the tibia. *J Bone Joint Surg Am.* 1985;2013:687-98.
- [3] Marmor L. An unusual fracture of the tibial epiphysis. *Clin Orthop Relat Res.* 1970;73:132-35.
- [4] Horn BD, Crisci K, Krug M, Pizzutillo PD, MacEwen GD. Radiologic evaluation of juvenile tillaux fractures of the distal tibia. *J Pediatr Orthop.* 2001;21:162-64.
- [5] Kumar N, Prasad M. Tillaux fracture of the ankle in an adult: A rare injury. *Journal of Foot and Ankle Surgery.* 2014;53(6):757-58.
- [6] Cooperman DR, Spiegel PG, Laros GS. Tibial fractures involving the ankle in children: the so-called triplane epiphyseal fracture. *J Bone Joint Surg (Am).* 1978;60-A:1040-46.
- [7] Cooper AP. On dislocation of the ankle joints. In: *A Treatise on Dislocations and on Fractures of the joints.* London, Longman, Hurst, Reese, Orme and Brown. E Cox and Son, 1822.

PARTICULARS OF CONTRIBUTORS:

1. Assistant Professor, Department of Orthopaedics, G.M.C and Hamidia Hospital, Bhopal, Madhya Pradesh, India.
2. Senior Resident, Department of Orthopaedics, G.M.C and Hamidia Hospital, Madhya Pradesh, India.
3. Private Practitioner, Satya Trauma Center, Varansi, Uttar Pradesh, India.

NAME, ADDRESS, E-MAIL ID OF THE CORRESPONDING AUTHOR:

Dr. Pankaj Kumar Mishra,
E-115/4, Shivaji Nagar, Bhopal-462016, Madhya Pradesh, India.
E-mail: drpankaj@yahoo.com

FINANCIAL OR OTHER COMPETING INTERESTS: None.

Date of Submission: **May 22, 2016**

Date of Peer Review: **Jun 11, 2016**

Date of Acceptance: **Sep 14, 2016**

Date of Publishing: **Mar 01, 2017**